

**PATIENT**

Chloe Warley

**SPECIES**

Canine

**BREED**

Cockapoo

**SEX**

Female Spayed

**AGE**

10 years

**WEIGHT**

19.7lbs

**PRESENTING CLINICAL SIGNS**

History: History grade III/VI systolic murmur. Recent coughing which sounds more tracheal in origin. Radiographs revealed a dorsal interstitial pattern. Was given one IV dose of Lasix. BP: 122mmHg. \*Sedated with butorphanol/alfaxalone.

**ECHOCARDIOGRAM FINDINGS**

2D, m-mode, color flow and Doppler imaging is available.

**Left ventricle:** Mild LV dilation with hyperdynamic function. LV wall thicknesses are normal.

**Left atrium:** The left atrium is severely enlarged and bulbous in appearance.

**Mitral valve:** Diffuse thickening of mitral valve leaflets (anterior> posterior) with prolapse into the left atrial lumen. Severe mitral regurgitation. Normal velocity.

**Aortic valve/Aorta:** The aortic valve is normal in morphology and mobility. No AI. Normal LVOT velocity.

**Right ventricle:** Normal RV dimension. No obvious RVH.

**Right atrium:** Mild atrial dilation.

**Tricuspid valve:** The tricuspid valve appears thickened with minimal septal prolapse. Moderate tricuspid regurgitation visualized. Velocity consistent with mild pulmonary hypertension.

**Pulmonic valve/Pulmonary artery:** The pulmonic valve is normal with normal pulmonic outflow velocity. No pulmonic insufficiency.

**Pericardium/other:** No pericardial or pleural effusion noted. No obvious cardiac masses.  
**Heart rhythm:** ECG reveals a sinus rhythm with an average HR of 100bpm.

**INTERPRETED BY**

Maggie Machen  
 Lamy, DVM  
 DACVIM (Cardiology)

**2-Dimensional Measurements**

Ao diam (cm)	1.5
LA diam (cm)	3.9
LA:Ao (Swe)	2.6
IVS thickness (cm)	0.8
LVID diastole (cm)	4.0
PW thickness (cm)	0.8
LVID systole (cm)	1.9
FS (%)	52

**Doppler Measurements**

PV Vmax (m/s)	1.5
AoV Vmax (m/s)	1.2
MR Vmax (m/s)	5.5
TR Vmax (m/s)	3.0
TR PG (mmHg)	36

**IMAGING**

**PERFORMED BY**

Pamela Harrigan,  
 RDCS

**INTERPRETATION OF THE FINDINGS**

Chronic degenerative valve disease causing severe mitral and moderate tricuspid regurgitation. Severe LA dilation indicates the risk for spontaneous congestive heart failure is high going forward. Early pulmonary hypertension is noted which should be monitored going forward. No additional issues such as systolic dysfunction is identified.

**HOSPITAL NAME**

Norfolk County  
 Veterinary Service

**REFERRING VET**

Dr. Richards

In light of a reported cough and severity of disease on echocardiogram, there is concern for early congestive heart failure even without reported congestion on films. Institution of full cardiac supportive medications is recommended as below, including low-dose Lasix therapy. Hydrocodone should also be considered for quality of life for any mechanical component.

**INVOICE**

23159

**DATE**

3/17/22

The average survival time of canine patients with active pulmonary edema is 8-9 months on medications, however they generally are able to maintain a good quality of life for that



**PATIENT**

Chloe Warley

period. Patient will always be at risk for recurrent CHF, development of arrhythmias/LA tear, syncope and/or sudden death in the future.

**SPECIES**

Canine

**RECOMMENDATIONS**

- Administer Furosemide 1mg/kg PO q12h.
- Administer Pimobendan 0.3mg/kg PO q12h.
- Institute Spironolactone 1-2mg/kg PO q12h.
- Pending response, consider hydrocodone with homatropine 0.2-0.4mg/kg up to q4-6 hours PRN for any residual mechanical cough in the face of normal sleeping respiratory rates.
- Monitor for development of a cough, labored breathing, exercise intolerance or collapse episodes.
- Monitoring of sleeping respiratory rates will be paramount to screen for congestive heart failure at home.
- Elective anesthesia is not advised.
- Omega fatty acid supplementation and mild salt restriction may be of some long-term benefit.

**BREED**

Cockapoo

**SEX**

Female Spayed

**AGE**

10 years

**WEIGHT**

19.7lbs

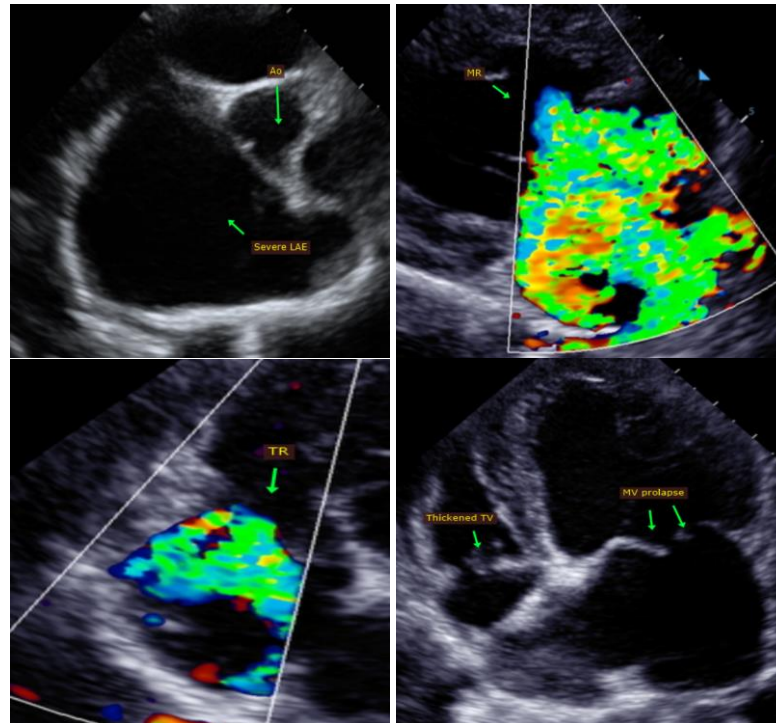
**PLAN**

- Monitor renal values and BP in 1-2 weeks. If BP >130mmHg, institute ACEI 0.5mg/kg PO q12h. Monitor renal panel/BP every 3-4 months lifelong.
- Recommend conservative monitoring with a recheck echocardiogram in 4-6 months, sooner if any development of clinical signs.

**INTERPRETED BY**

Maggie Machen  
 Lamy, DVM  
 DACVIM (Cardiology)

**IMAGES**



**IMAGING PERFORMED BY**

Pamela Harrigan,  
 RDCS

**HOSPITAL NAME**

Norfolk County  
 Veterinary Service

**REFERRING VET**

Dr. Richards

**INVOICE**

23159

**DATE**

3/17/22



**PATIENT**

Chloe Warley

**SPECIES**

Canine

**BREED**

Cockapoo

**SEX**

Female Spayed

**AGE**

10 years

**WEIGHT**

19.7lbs

**INTERPRETED BY**

Maggie Machen  
Lamy, DVM  
DACVIM (Cardiology)

**IMAGING  
PERFORMED BY**

Pamela Harrigan,  
RDCS

**HOSPITAL NAME**

Norfolk County  
Veterinary Service

**REFERRING VET**

Dr. Richards

**INVOICE**

23159

**DATE**

3/17/22

The information and recommendations provided are based on the images presented by the referring veterinarian. No evaluation can be communicated regarding pathology that was not visible in the image/video clips provided.

Thank you for this referral. This report was generated using transcription software, and minor dictation errors may be present. If the clinical or image interpretation does not parallel your findings or if I can be of any further assistance, please contact me.

Maggie Machen Lamy, DVM  
Diplomate of the American College of Veterinary Internal Medicine (Cardiology)  
info@sonopath.com